



**EK PARIVARTAN FOUNDATION REGISTRATION NO: 130**

**EK PARIVARTAN FOUNDATION PAN NO: AAATE9879M**

**EK PARIVARTAN FOUNDATION 80G NO: AAATE9879MF20221**

**EK PARIVARTAN FOUNDATION NGO DARPAN : DL/2019/0230573**

**EK PARIVARTAN FOUNDATION GUIDESTAR INDIA : 11308**

**EK PARIVARTAN FOUNDATION CSR REG NO : CSR00040314**

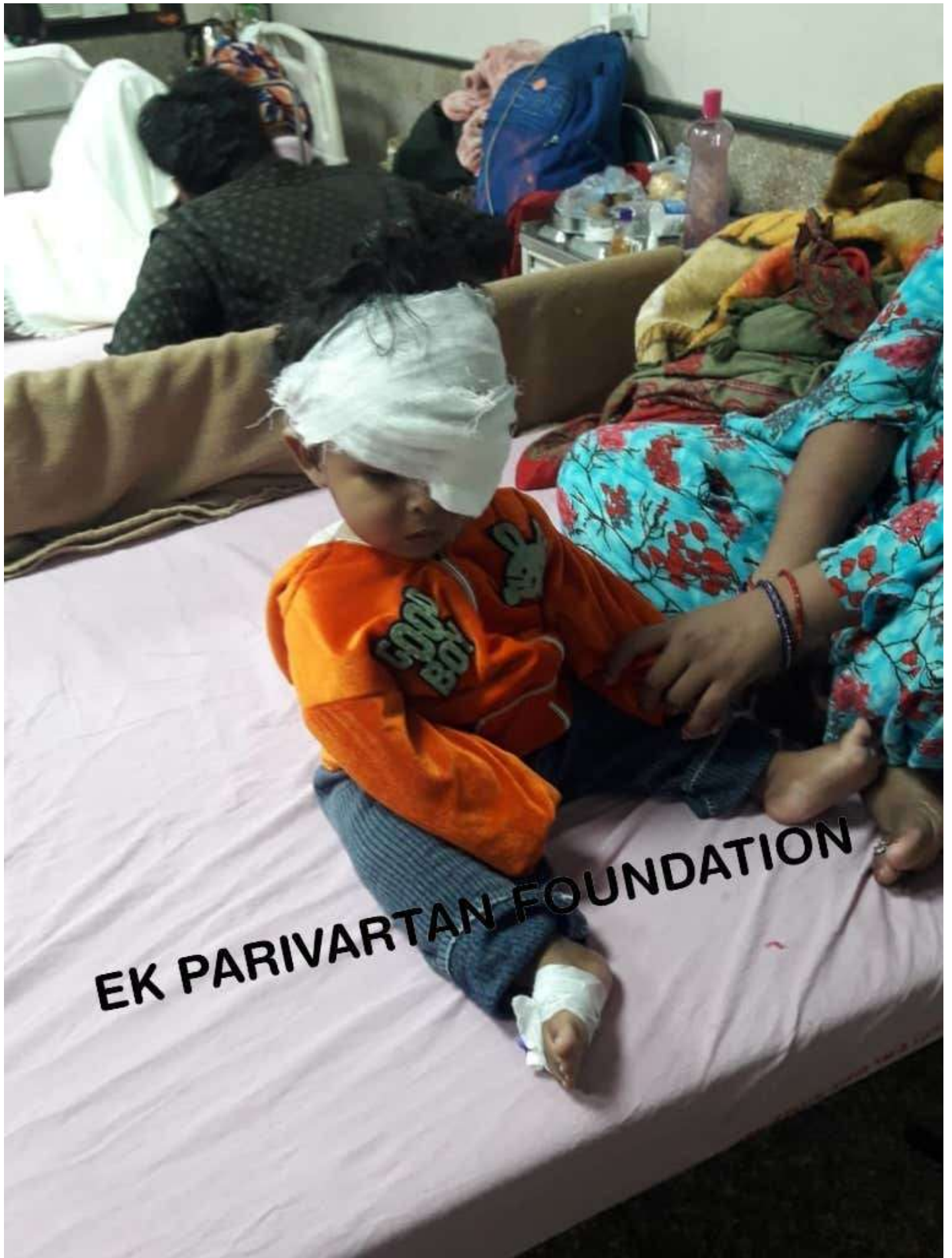**EK PARIVARTAN FOUNDATION TM APP NO : 5822870**

**EK PARIVARTAN FOUNDATION MSME NO : DL-02-0040746**

**EK PARIVARTAN FOUNDATION WEBSITE : [WWW.EPFNGO.ORG](http://WWW.EPFNGO.ORG)**

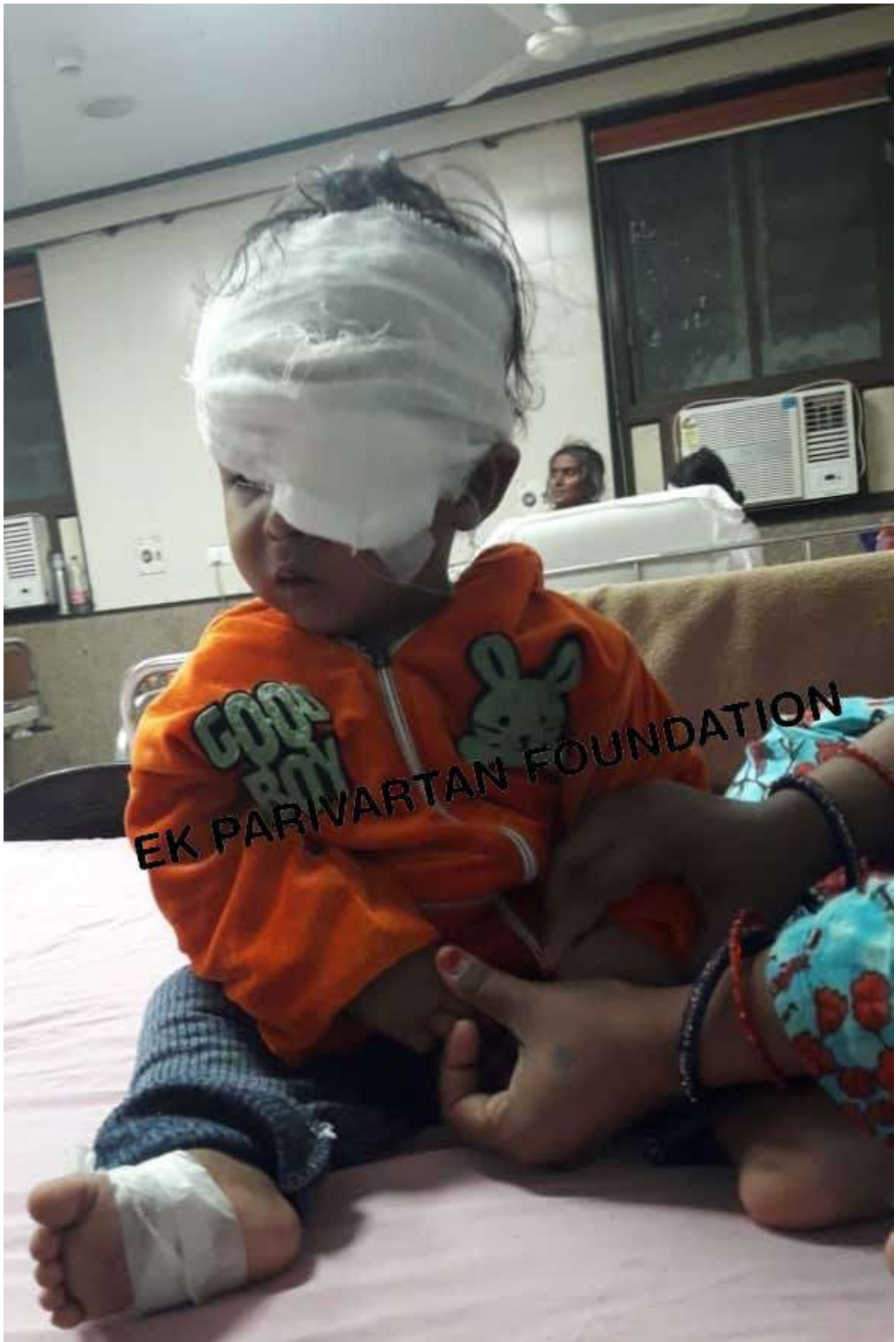**EK PARIVARTAN FOUNDATION E-MAIL : [INFO@EPFNGO.ORG](mailto:INFO@EPFNGO.ORG)**

|                                  |   |
|----------------------------------|---|
| <b>PATIENT NAME</b>              | <b>BABY SHREYA KUMARI</b>                             |
| <b>PATIENT FATHER NAME</b>       | <b>MR. AJAY KUMAR</b>                                 |
| <b>DOB AND GENDER</b>            | <b>2 YR / FEMALE</b>                                  |
| <b>DISEASE NAME</b>              | <b>EYE CANCER</b>                                     |
| <b>TREATMENT HOSPITAL</b>        | <b>(AIILS) ALL INDIA INSTITUTE OF MEDICAL SCIENCE</b> |
| <b>REGISTRATION NO</b>           | <b>108103361</b>                                      |
| <b>DEPARTMENT NAME</b>           | <b>PAEDIATRICS</b>                                    |
| <b>TREATMENT COST</b>            | <b>APPROX 2 TO 3 LAKH</b>                             |
| <b>PATIENT FATHER OCCUPATION</b> | <b>LABOR</b>  |
| <b>PATIENT ADDRESS</b>           | <b>KUKURGHATI, DEORIA, UP 274702</b>                  |



**EK PARIVARTAN FOUNDATION**





**EK PARIVARTAN FOUNDATION**

दिनांक - Date

उपचार - Treatment

(A2) RB clemi  
opuon

growp mehin clear  
Dir 2. macula healthu.  
grows ditud glen o nans ent.  
510 RB.

- Dr. Loni Sr  
pls opuon  
OPD # 33  
wed/sat.

  
**EK PARIVARTAN FOUNDATION**

नेत्र ईश्वरीय सर्वश्रेष्ठ उपहार है जिनका मनुष्य जीवन में दान करना परमश्रेष्ठ है।

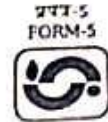इनकी पूर्ण रक्षा कीजिए ताकि ये अपनी रक्षा कर सकें।

Eyes are God's most precious gift to man kind and eye donation is the most noble deed.

Take full care of them so that they can take care of you.



बिहार सरकार  
GOVERNMENT OF BIHAR  
योजना और विकास विभाग  
DEPARTMENT OF PLANNING AND DEVELOPMENT  
प्राथमिक स्वास्थ्य केंद्र भोरे  
PRIMARY HEALTH CENTRE BHORE



जन्म प्रमाण-पत्र  
BIRTH CERTIFICATE

(जन्म प्रमाण-पत्र अधिनियम, 1969 की धारा 12 / 17 तथा बिहार जन्म मृत्यु रजिस्ट्रेशन नियम, 1999 के नियम 8/13 के अंतर्गत जारी किया गया)  
(ISSUED UNDER SECTION 12/17 OF THE REGISTRATION OF BIRTHS & DEATHS ACT, 1969 AND RULE 8/13 OF THE BIHAR REGISTRATION OF BIRTHS & DEATHS RULES 1999)

यह प्रमाणित किया जाता है निम्नलिखित सूचना जन्म के मूल अभिलेख से ली गई है जो कि प्राथमिक स्वास्थ्य केंद्र भोरे तहसील भोरे जिला गोपालगंज राज्य/संघ प्रदेश बिहार, भारत के रजिस्ट्रार में उल्लिखित है।  
THIS IS TO CERTIFY THAT THE FOLLOWING INFORMATION HAS BEEN TAKEN FROM THE ORIGINAL RECORD OF BIRTH WHICH IS THE REGISTER FOR PRIMARY HEALTH CENTRE BHORE OF TAHSIL/BLOCK BHOREY OF DISTRICT GOPALGANJ OF STATE/UNION TERRITORY BIHAR, INDIA.

नाम / NAME: SHREYA KUMARI

लिंग / SEX: महिला / FEMALE

जन्म तिथि / DATE OF BIRTH: 29-01-2023  
TWENTY-NINTH JANUARY-TWO THOUSAND TWENTY THREE

जन्म स्थान / PLACE OF BIRTH: PRIMARY HEALTH CENTRE BHORE

माता का नाम / NAME OF MOTHER: PHULKUMARI

पिता का नाम / NAME OF FATHER: AJAY KUMAR

आधार नंबर / MOTHER'S AADHAAR NO:

आधार नंबर / FATHER'S AADHAAR NO:

बच्चे के जन्म के समय माता-पिता का पता / ADDRESS OF PARENTS AT THE TIME OF BIRTH OF THE CHILD: NANPUR, KUKUR GHATI, BHATPAR RANI, DEORIA, UTTAR PRADESH

माता-पिता के स्थायी पता / PERMANENT ADDRESS OF PARENTS:

NANPUR, KUKUR GHATI, BHATPAR RANI, DEORIA, UTTAR PRADESH

पंजीकरण संख्या / REGISTRATION NUMBER: B-2023-10-08536-000724

पंजीकरण तारीख / DATE OF REGISTRATION: 31-03-2023

टिप्पणी / REMARKS (IF ANY):

जारी करने की तिथि / DATE OF ISSUE: 31-03-2023

जारी करने वाला प्राधिकारी / ISSUING AUTHORITY:

प्रवर्ती निदेशिका/पदाधिकारी  
REGISTRAR (BIRTH & DEATH)  
प्राथमिक स्वास्थ्य केंद्र भोरे  
PRIMARY HEALTH CENTRE BHORE

(सोपातबंध)

UPDATED ON: 31-03-2023 13:27:14



"THIS IS A COMPUTER GENERATED CERTIFICATE."  
"THE GOVT OF INDIA VIDE CIRCULAR NO. 1/12/2014 VS(CRS) DATED 27 JULY 2015 HAS APPROVED THIS CERTIFICATE AS A VALID LEGAL DOCUMENT FOR ALL OFFICIAL PURPOSES".

\* प्रत्येक जन्म एवं मृत्यु का पंजीकरण सुनिश्चित करें / ENSURE REGISTRATION OF EVERY BIRTH AND DEATH \*





# Anaesthesia Record

Dr. Rajendra Prasad Centre for Ophthalmic Sciences  
All India Institute of Medical Sciences, New Delhi-110029

Name: *Shruti* Age/Sex: *2yr/F* UHID: *108103311* Ht/Wt: *10kg* CR.No.  
ASA Grade: 1 2 3 4 5 E Diagnosis: *R.A.* Procedure: *EUA* Mobile No.

Significant history/ medication:

*PTSD / CAB / No H/O New stay  
No H/O. CR*

Prematurity: Yes  No

Post gestational age:

Cyanosis / apnoea:

Previous Anaesthesia Exposure & its complications:

Congenital Anomalies/Syndrome:

Airway examination: Mouth opening: Mallampati Class *III* Tongue

Neck movements Retrognathia High arched/velv. palate Tonsils

Intubation: simple difficult

Respiratory System: Resp. Rate *60-80/Min* Auscultation

Cardiovascular System: Pulse rate/ Heart rate *110/Min* Heart Sounds Murmur

Any Significant finding Preop.SpO<sub>2</sub>

IV access: Easy / Difficult

Nervous System: MR / Delayed mile stones / CP / Seizures

Musculoskeletal system examination: head holding / difficulty in walking/ climbing stairs/  
doing every day tasks

Investigations: HB RFT LFT TFT

X-Ray Chest ECG ECHO

CT Brain MRI

CID/W Dr Sumit.

DIF + Snuclabation →

DA A. B1  
19/2/25  
Wood 1A  
7:30AM ✓

B1E  
EUA myah 3T 10x  
5 days.

Flupic CE-MRI brain. Orbit. 2mm cube  
↓ (fat supp) empty o. No pineal gland.

(53/Mon/10:00.Am)

(114)

EK PARIVARTAN FOUNDATION  
SR

ब. रो. वि. कार्ड  
O.P.D. Card

राजेन्द्र प्रसाद नेत्र विज्ञान केन्द्र  
वा. आ. नं. ३३ दिल्ली-११००१०

Rajend  
J.M.S.

रज.आई.  
IID No

रोग  
Name



UHID: 108103361  
ABNA  
Card No. 20200001423

डॉ. सुश्री / SHREYA KUMARI

DO. ALAY KUMAR

DO. ALAY KUMAR

DO. ALAY KUMAR

DO. ALAY KUMAR

DO. ALAY KUMAR

DO. ALAY KUMAR

दृष्टि



अनुभाग व दिन  
Section and Day  
मंगलवार व शुक्रवार  
Tuesday & Friday

कमरा नंबर  
Cabin No.

रज.आई. 27

कमरा / Room: 3

Unit-II

RPC CPC

Dr. Shree Nar

I का एकक

EK PARIVARTAN FOUNDATION



Registration time  
04/02/2020 07:23:51 AM

| दिनांक<br>DATE | निदान<br>DIAGNOSIS       |
|----------------|--------------------------|
|                | (A) Retinal Myeloma (BE) |

उपचार Treatment

Recent noticed white reflex @ left  
to start eye

(E) Leucocoe +

Atv

(D)

(E) USG (PSE)

RAPD +

(No calcification (PSE)  
RA, ICH

large intracard  
mass i  
specks of  
calcification

(P)

MC MC MC - COPAC

(Photography)

(U)

gently  
function

s/o RB

इस कार्ड को सुरक्षित रखें तथा अस्पताल में दिखाने के समय हर वक्त साथ लायें।

Kindly keep this Card safety and bring it on your follow-up visits

1. धूम्रपान निषेध
2. दृष्टि कार्ड केवल दृष्टिदान में ही रखें
3. बुझिये नहीं
1. No Smoking
2. Use Double
2. No Spitting

*[Signature]*





दिनांक - Date

उपचार - Treatment

~~D.O.A. 15/2/25~~

~~Ward 1A~~

8:30 AM

35 → Taparkh

# EK PARIVARTAN FOUNDATION

NRC ward 1A

Munday 10/2/25

@ 10 AM

EVA date to be given after NRC.

12/2/25

7th floor

7:30 am.

NPO explained

8 hrs  
2 hrs  
liquid

नेत्र ईश्वरीय सर्वश्रेष्ठ उपहार है जिनका मनुष्य जीवन में दान करना परमश्रेष्ठ है।  
इनकी पूर्ण रक्षा कीजिए ताकि ये अपनी रक्षा कर सकें।  
Eyes are God's most precious gift to man kind and eye donation is the most noble deed.  
Take full care of them so that they can take care of you.

व. रो. वि. कार्ड  
O.P.D. Card



अनुभाग व दिन  
Section and Day VI  
बुधवार व शनिवार  
Wednesday & Saturday

कमरा नंबर  
Cabin No.

डा. राजेन्द्र प्रसाद नेत्र विज्ञान केन्द्र  
अ. भा. आयु. सं., नई दिल्ली-110029

Dr. Rajendra Prasad Centre for Ophthalmic Sciences  
A.I.I.M.S., New Delhi-110029

यू.एच.आई.डी. संख्या  
UHID No. 108103361

आचार्य राधिका टंडन का एकक  
Prof. Radhika Tandon's Unit

| रोगी का नाम<br>Name of the Patient | पुत्र/पुत्री/पत्नी<br>S/D/W | लिंग<br>Sex | आयु<br>Age | पता<br>Address |
|------------------------------------|-----------------------------|-------------|------------|----------------|
| Shreyan Kumari                     | 2y/12                       |             |            |                |

| दिनांक<br>DATE | निदान<br>Diagnosis |
|----------------|--------------------|
| 10/2/25        |                    |

**EK PARIVARTAN FOUNDATION**

उपचार Treatment  
NRC ↓ unit 6

Ⓡ RB Reaching upto retinal area.  
S/O gp ERB.  
- optic nerve WNL ON Ⓡ based on T<sub>2</sub> scan  
- Pituitary gland WNL. No contrast scan available

Ⓢ Intraocular mass Ⓢ Int.

→ Ⓛ WNL  
Patient to Review in NRC. Ⓢ 53 with  
CD | Repeat CEMRI //

Admct - EVA. (11/2/25).

कृपया इस कार्ड को सुरक्षित रखें तथा अस्पताल में दिखाने के समय हर वक्त साथ लायें।

Kindly keep this Card safely and bring it on your follow-up visits.

1. धूम्रपान निषेध 2. फूड़ा कर्कट केवल फूड़ेदान में ही खालें 3. धूकिये नहीं
1. No Smoking 2. Use Dustbin 3. No Spitting

Date: 10/2/25

NRC Discussion:

NRC / ↓ Unit 6

② RB reaching upto retrochiasmatic area  
slo of E RB

Optic nerve WNL.

Pineal gland WNL.

ON Normal based on T2 scan.

No contrast scan available.

④ WNL.

**EK PARIVARTAN FOUNDATION**

Ref: 15 ECA TGA. Dated 11/2/25

TH floor

8AM

NPO explained



11/2/25

STAINING FOR Unit 6 / Dr Sumit / Dr Tapas / DT Nishant

OP

OS

DS

cornea clear  
no ectropion uvea  
no m  
lens clear

WNL


cornea clear  
no ectropion uvea  
no nvi  
lens clear

PS

lots of vitreous &  
subretinal seeds  
mass fill entire VC

WNL

# EK PARIVARTAN FOUNDATION



UDM R/E: lens touch + hit

⊖ (R) group ⊕ E RB  
⊖ WNL

USG R/E: Large mass, hyperechoic, heterogenous  
mod - high compressed spikes slo  
calcification

Date: 2/2/25

Clinical History:

parent noticed white reflex (RE) x 2 mths ago.

(R) leucocoria + RAPD.

(RE) USG (TSE)

(No calcifial; DHPV), - large intraocular  
RD, VH: mass & specks of  
calcification

Presenting Complaints:

(LE) grossly anechoic.

S/O RB.

# EK PARIVARTAN FOUNDATION

in / glass + media clear  
clear name healthy  
covered glass: ? mass @  
S/O RB

8/2/25  
Pedigree Chart:

C/S/B Dr Loni consultant

(R) leucocoria | Evaluated (S/O RB)

Date for EUS Next wk

Review for NRE on Monday @  
MRI film.

NRE RB clinic Registration

18

# ब. रो. वि. कार्ड O.P.D. Card



अनुभाग व दिन  
Section and Day VI  
बुधवार व शनिवार  
Wednesday & Saturday

कमरा नंबर  
Cabin No.

डा. राजेन्द्र प्रसाद नेत्र विज्ञान केन्द्र  
अ. भा. आयु. सं., नई दिल्ली-110029

Dr. A. S. K. U. M. I. S. H. R. E. Y. A. K. U. M. A. R. I.  
UHID: 108103361  
ABNA  
कमरा / Room: 33  
Unit-VI  
RPC OPD  
Dr. Newele Lomi  
WED, SAT  
शुभ, शनि  
Registration time:  
08/02/2025 09:34:14 AM

का एकक  
London's Unit  
पता  
Address

दिनांक DATE निदान DIAGNOSIS उपचार Treatment

08 Feb 2025

## EK PARIVARTAN FOUNDATION

*(R) Leucocytosis & Eucalcemia ? PDB*  
*(348) Dr. Mangy Jls*

*date for EENT surgery next week.*

*Review for NRC on Monday  
MRI film room (53) 10:00*

Kindly keep this Card safely and bring it on your follow-up visits.

- 1. धूम्रपान निषेध 2. कूड़ा कर्कट केवल कूड़ेदान में ही डालें 3. थूकिये नहीं
- 1. No Smoking 2. Use Dustbin 3. No Spitting

*(PRC) RB Clinic report*

- 1. धूम्रपान निषेध 2. कूड़ा कर्कट केवल कूड़ेदान में ही डालें 3. थूकिये नहीं
- 1. No Smoking 2. Use Dustbin 3. No Spitting





ALL INDIA INSTITUTE OF MEDICAL SCIENCES, GORAKHPUR

शरीर स्वास्थ्य और जनसंख्या विभाग

(A Joint Venture between AIIMS Gorakhpur & HLL Lifecare Limited)

+ HINDLABS

|                   |               |                     |                    |
|-------------------|---------------|---------------------|--------------------|
| Patient Name      | SHREYA KUMARI | Patient ID          | MLIAGRP16212       |
| Patient age / Sex | 002Years/F    | Referring Physician |                    |
| Bill Number       |               | Report Date / Time  | 21 Jan 2025 / 6:30 |
| Modality          | MR            |                     |                    |

# EK PARIVARTAN FOUNDATION

## MRI BRAIN AND ORBIT

MRI of brain & orbits has been performed using T1, T2W, FLAIR Diffusion and gradient sequence in multiple planes.

### Imaging Features:-

Brain parenchyma appears normal. Bilateral basal ganglia and thalami are symmetrical and reveal normal signal intensity. The brainstem and cerebellum appear normal. There is no evidence of cerebellar tonsil ectopia. Corpus callosum appears normal. There is no evidence of sellar widening. The ventricular system is normal. No abnormal extra-axial fluid is seen. No focal mass lesion is seen. No acute infarct is seen on diffusion sequence. No abnormal susceptibility is seen on gradient sequence to suggest hemorrhage. The grey white differentiation is preserved. Normal intracranial flow voids are well visualized. Limited evaluation of paranasal sinuses does not reveal any significant abnormality.


### MRI ORBIT.

Both the globes appear normal except for right eyeball which shows mildly T1 hyperintense and T2 hyperintense contents in vitreous suggestive of possibility of vitreous hemorrhage. Both the optic nerves are normal in course, caliber and signal intensity. The medial rectus, lateral rectus, superior rectus and inferior rectus muscles appear normal in course, caliber and signal intensity on both sides.

### Comments:-

Normal brain study.  
Possibility of vitreous hemorrhage in right eye.

Arpreet Singh Saini  
DNB  
0 8198800260





ALL INDIA INSTITUTE OF MEDICAL SCIENCES, GORAKHPUR

अखिल भारतीय आयुर्विज्ञान संस्थान, गोरखपुर

(An Joint Venture between AIIMS Gorakhpur & HLL Lifecare Limited)



|                   |                 |                                 |                        |
|-------------------|-----------------|---------------------------------|------------------------|
| Patient Name      | : SHREYA KUMARI | Patient ID                      | : HLLAGKP34232         |
| Patient age / Sex | : 002Years/F    | Referring Physician             |                        |
| Bill Number       |                 | <b>EK PARIVARTAN FOUNDATION</b> |                        |
| Modality          | : MR            |                                 |                        |
|                   |                 | Report Date / Time              | : 21-Jan-2025/<br>6:38 |

**MRI BRAIN AND ORBIT**

MRI of brain & orbits has been performed using T1, T2W, FLAIR Diffusion and gradient sequence in multiple planes.

**Imaging Features:-**

Brain parenchyma appears normal. Bilateral basal ganglia and thalami are symmetrical and reveal normal signal intensity. The brainstem and cerebellum appear normal. There is no evidence of cerebellar tonsil ectopia. Corpus callosum appears normal. There is no evidence of sellar widening. The ventricular system is normal. No abnormal extra-axial fluid is seen. No focal mass lesion is seen.

No acute infarct is seen on diffusion sequence. No abnormal susceptibility is seen on gradient sequence to suggest hemorrhage. The grey white differentiation is preserved. Normal intracranial flow voids are well-visualized. Limited evaluation of paranasal sinuses does not reveal any significant abnormality.

**MRI ORBIT;**

Both the globes appear normal except for right eyeball which shows mildly T1 hyperintense and T2 hyperintense contents in vitreous suggestive of possibility of vitreous hemorrhage. Both the optic nerves are normal in course, caliber and signal intensity. The medial rectus, lateral rectus, superior rectus and inferior rectus muscles appear normal in course, caliber and signal intensity on both sides.

**Comments:-**

***Normal brain study.***

***Possibility of vitreous hemorrhage in right eye. .***

Dr Harpreet Singh Saini

DMRD, DNB

Reg No: 8198800260